

Immunohistochemistry and genomic pathology for molecular targeted cancer therapy

Robert Y. Osamura, MD

International University of Health and Welfare (IUHW)
Diagnostic Pathology Center IUHW Mita Hospital

Recently, one of the major advances in cancer treatment is molecular target therapy which includes several major methods, (1) humanized monoclonal antibodies, (2) tyrosine kinase inhibitors, (3) signal transduction inhibitors, (4) hormonal analogues. The prediction of therapeutic effects depends on the detection of target molecules. Typical examples are (1) detection of HER2 gene over-expression and amplification in breast and gastric cancers, (2) mutations in several genes, i.e. EGFR for lung cancer, KRAS gene in lung and colo-rectal cancers, KIT gene in gastro-intestinal stromal tumor(GIST), (3) detection of activated transduction signals for renal cell carcinoma(RCC) and neuroendocrine tumors(NET), (4) hormone receptors in neuroendocrine tumors(NET).

This lecture outlines the contribution of immunohistochemistry and molecular pathology in molecular targeted cancer therapy and highlights the contribution of immunohistochemistry to predict the therapeutic effects.

Molecular targeted therapy

1. Humanized monoclonal antibodies

Trastuzumab(Herceptin)	HER2 (EGFR2)	BC GC
Retuximab(Retaxan)	CD20	Lymphoma
Bevacizumab(Avastin)	VEGF	CRC
Cetuximab(Erbitux)	EGFR1	CRC
2. Kinase inhibitors(TKI)

Imatinib(Glivec)	KIT	GIST
Gefitinib(Iressa)	EGFR1	Lung carcinoma
Erlotinib (Tarceva)	EGFR1	
Dasatinib Nilotinib Sunitinib	EGFR1	
Lapatinib(Tykerb)	EGFR1 and EGFR2	
Crizotinib(Xalkori)	ELM4-ALKfusion gene	Lung carcinoma
	BRAF mutation	thyroid
3. Signal transduction inhibitors(STI)

Everolimus(Afinitor)	mTOR	RCC PNET
----------------------	------	----------
4. Hormone analog

Octreotide(Sandostatin)	STTR	NET
-------------------------	------	-----

Summary of immunohistochemical and genetic tests

For molecular targeted cancer therapy

Breast and gastric cancer

HER2 IHC positive or ISH positive → Trastuzumab

Lung adenocarcinoma

EGFR mutated & KRAS wild type → gefitinib

EGFR non-mutated & ALK translocation → crizotinib

Colo-rectal cancer

EGFR positive, KRAS wild & BRAF wild → cetuximab

GIST

KIT exon 11 mutated- imatinib

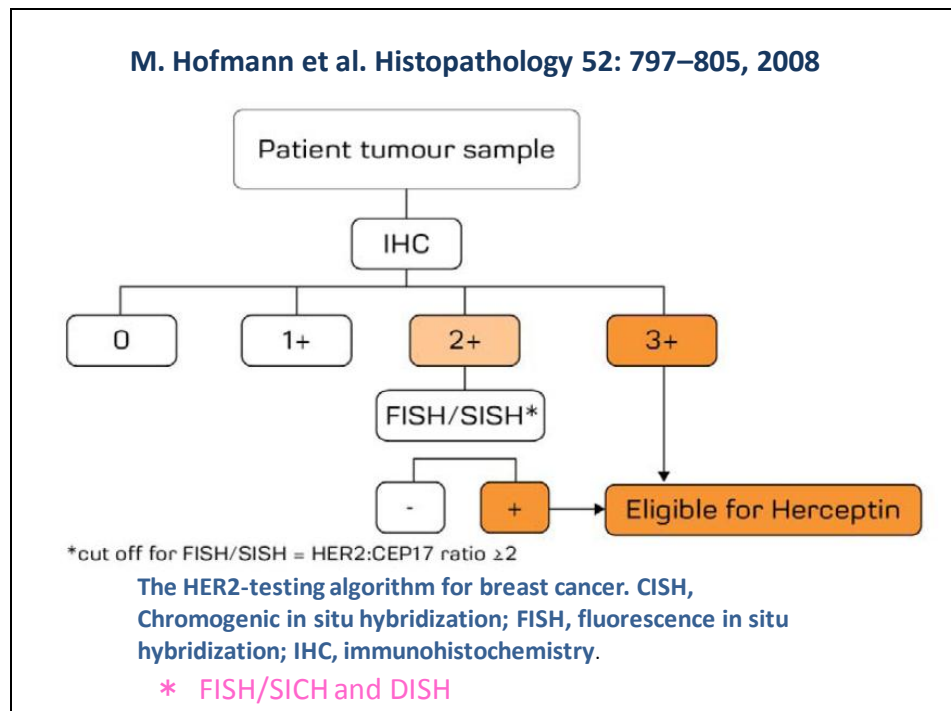
NET

SSTR2a overexpressed → somatostatin analogue

1. HER2 gene over-expression and amplification in breast cancer(BC) and gastric cancers(GC)

It has been well known that humanized monoclonal antibody trastuzumab now is approved and used for metastatic BC (approved 2001 in Japan), adjuvant therapy (2008 approved in Japan), and neoadjuvant, therapy (approved 2011 in Japan) for the breast cancer.

Current diagram in most institutions in Japan is to start IHC first and followed by genetic tests for equivocal case.



This algorithm has been modified by ASCO/CAP in 2007.

In 2011, Trastuzumab has been approved for GC Methodology: For IHC, polyclonal antibody, HercepTest®(DAKO) or monoclonal antibody 4B5(Roche, Ventana) are used. For genetic test, in situ hybridization(ISH) is the method of choice. FISH is the first method, but now CISH and further DISH are approved and used for the evaluation of HER2 gene amplification. ISH with bright field would be superior to FISH on the particular tumors with HER2 heterogeneity, such as gastric cancer.

2. Mutations of EGFR, KRAS, BRAF, KIT in lung cancers, colo-rectal cancers, GISTs

Gene mutation is another test to predict the therapeutic effects of molecular target therapy. EGFR mutation is essential genetic change for the effective therapy of lung adenocarcinoma by gefitinib

Lung cancers

It has been very well known that the therapeutic effects of gefitinib are correlated with the mutation of EGFR gene, (1) point mutation of Exon 21 L858R and (2) deletion mutation of Exon 19. 746-750. Both mutations account for approximately 90% of all EGFR mutations(FIG). The mutations are most frequently occurring in adenocarcinoma, more often in Asian women and never smokers. And it has also been known that immunohistochemical staining for EGFR is not related to the therapeutic effects.

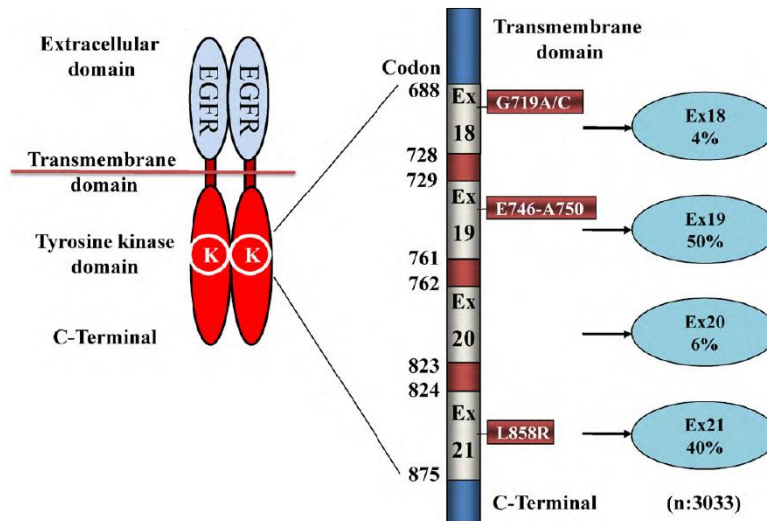
If the lung cancers show mutation in KRAS gene and BRAF gene, it has been suggested that gefitinib is not effective even though the tumor cells exhibit EGFR mutation.

Screening a panel of 340 paraffin-embedded NSCLC tumor samples with these antibodies showed that the sensitivity of the immunohistochemistry assay is 92%, with a specificity of 99% as compared with direct and mass spectrometry - based DNA sequencing. This simple assay for detection of EGFR mutations in diagnostic human tissues provides a rapid, sensitive, specific, and cost-effective method to identify lung cancer patients responsive to EGFR-based therapies (Jian Yu et al. 2009)

Furthermore, EGFR mutation and EML4-ALK translocation are mutually exclusive. Therefore, if the tumor cells are negative for EGFR mutation, we have to examine the possible EML4-ALK translocation. It is well known that immunohistochemical staining for ALK correlates with EML4-ALK translocation. By FISH, EML4-ALK translocation can be identified as “break apart” mutation. This translocation can occur with mutual exclusion of EGFR & KRAS mutation

Recently, EGFR mutation-specific monoclonal antibodies have been available to detect mutations of Exon 21 L858R and Exon 19 del746-750. Both antibodies show high specificity and sensitivity. The mutation-specific antibodies are suggested to be used as prescreening for gefitinib therapy.

Yoshida T et al. *Biochem Pharmacol.* 2010 May 25. [Epub ahead of print]



Frequency of EGFR mutations in NSCLC (n = 3033)

Colo-rectal cancers

For the metastatic colorectal cancers, humanized anti-EGFR monoclonal antibody, cetuximab, has been used as a therapy if the colo-rectal cancers(CRCs) cells are immunohistochemically positive for EGFR. It has been known that the cetuximab therapy is not effective when the tumor cells contain KRAS mutation or BRAF mutation. So cetuximab therapy should be given to the patients with wild KRAS or BRAF genes.

KRAS mutational analysis is mandatory for appropriate cetuximab therapy. The detection methods include PCR direct sequencing or Kit: Scorpion-ARMS(Roche Diagnostics). It is essential to perform mutational analysis on the tissue sections which contain adequate carcinoma. This requires the practical role of pathologists.

The following is the manufacturer's package insert for the colo-rectal cancers:

Erbix® is an epidermal growth factor receptor (EGFR) antagonist indicated for treatment of:

Colorectal Cancer

K-Ras mutation-negative (wild-type), EGFR-expressing, metastatic colorectal cancer as determined by FDA-approved tests

- In combination with FOLFIRI for first-line treatment,
- In combination with irinotecan in patients who are refractory to irinotecan-based chemotherapy,
- As a single agent in patients who have failed oxaliplatin- and irinotecan-based chemotherapy or who are intolerant to irinotecan

Limitation of Use: Erbitux (cetuximab) is not indicated for treatment of K-Ras mutation-positive colorectal cancer.

Gastrointestinal stromal tumor(GIST)

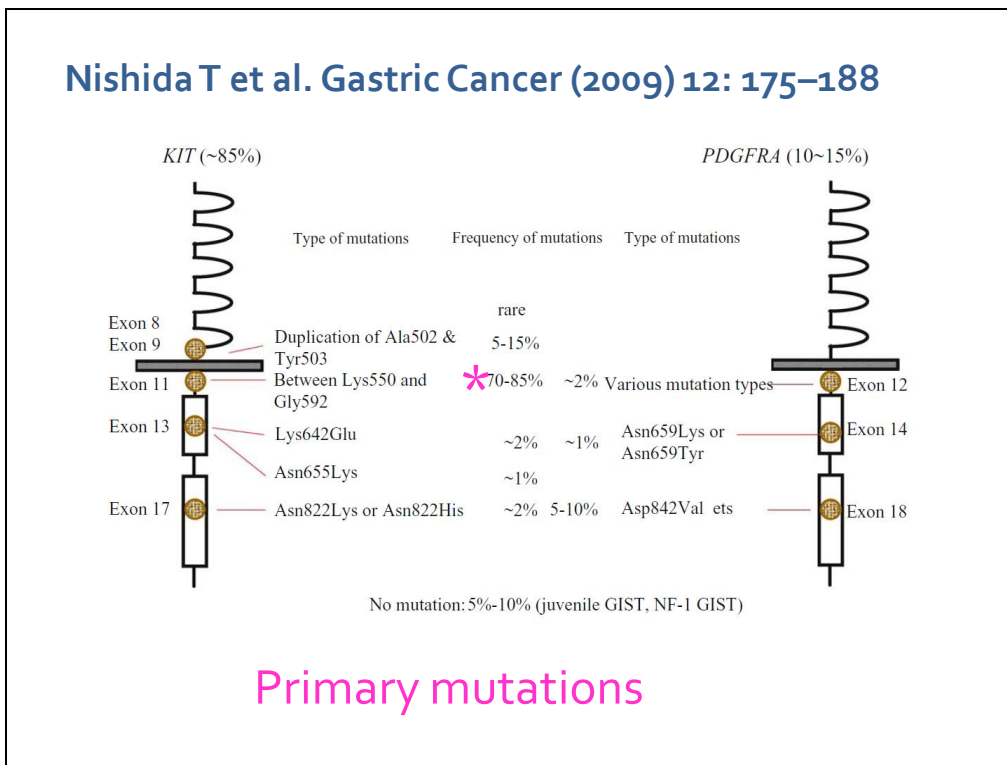
GISTs are the most common mesenchymal neoplasms of the GI tract; Imatinib is a tyrosine kinase inhibitor(TKI) when the tumor cells have KIT and PEGFRA active mutations. The first mutation is thought to be oncogenic and the second mutation is related drug resistance.

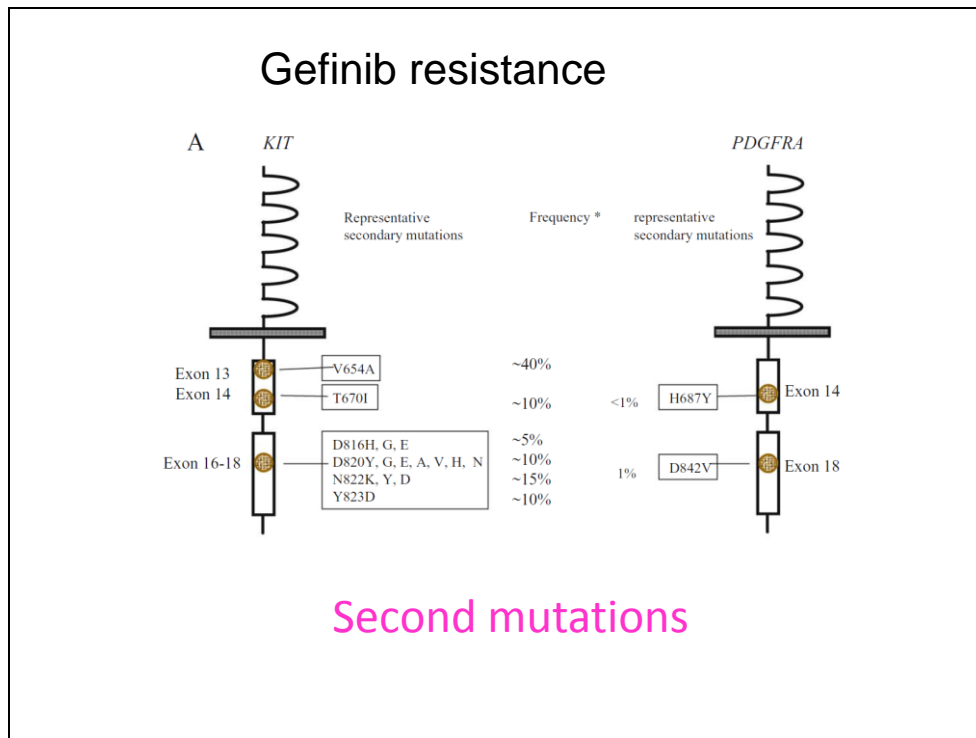
KIT mutation in Exon 11 is most common and the tumors with its deletion are more aggressive. Exon 11 mutation correlates well with the imatinib therapy. The GISTs with Exon 9 mutation occur more in the intestinal tract and less sensitive for imatinib.

PDGFRA mutation occurs most often in Exon 18 and resistant to imatinib therapy.

The secondary mutations which are related to imatinib resistance occur in Exon 13 and 17. The GISTs with the mutation in Exon 13 and 17 are responsive to sunitinib.

Thus, mutational analysis in KIT and PFGFRA genes is essential for the therapeutic predictive factor for therapy.





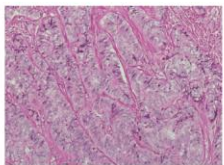
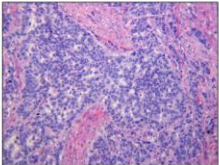
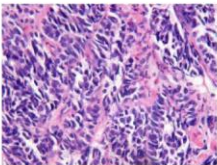
3. Somatostatin receptor SSTR2a in NETs

It has been well known that somatostatin receptor (SSTR) is composed of five subtypes, SSTR1, SSTR2a, SSTR3, SSTR4 and SSTR5. All SSTRs are localized on the cell membrane. **The** neuroendocrine tumors which express SSTR2a are expected to respond to the somatostatin analog therapy, Octreotide.

Recent classification of neuroendocrine neoplasms (NEN) are composed of neuroendocrine tumor (NET) G1 and G2 and neuroendocrine carcinoma (NEC) and mixed adenoneuroendocrine carcinoma (MANEC). To differentiate NET G1, NETG2 and NEC, proliferative markers, mitotic indices and Ki67 labeling indices are used.

WHO Classification 2010

ICD-O codes		Ki67	Mitoses/10HPF
Neuroendocrine tumour (NET)			
NET G1 (carcinoid)	8240/3	≤ 2%	< 2
NET G2	8249/3	3–20%	2–20
Neuroendocrine carcinoma (NEC)			
Large cell NEC	8246/3	> 20%	> 20
Small cell NEC	8041/3		
Mixed adenoneuroendocrine carcinoma (MANEC)			
	8244/3		

NET G1
NET G2
NEC Small cell type

NET G1 and NET G2 more frequently express SSTR2a and are expected to respond to SA therapy. In our experience, approximately 60% of NETs are positive for SSTR2a and about 70% of them are responsive to SA therapy including stable disease condition.

Recently, mTOR inhibitor, Everolimus, has been approved for the therapy of the pancreatic NETs. Immunohistochemical staining for p-mTOR appears to be correlated to the therapeutic response.

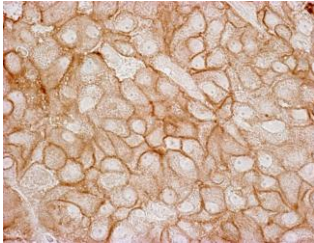
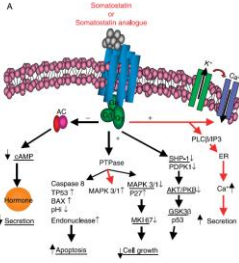
Volante et al 2007 defined the interpretation of SSTR2a according to the pattern of staining to score 0, 1 2 and 3. Score 2 and 3 are membranous staining are interpreted as “positive”.

Biotherapy SSTR





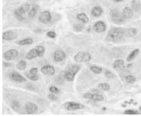
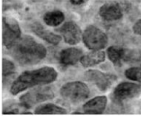
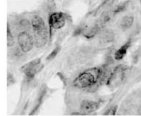
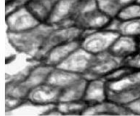
Somatostatin receptor detection for the therapy of somatostatin analogues

Somatostatin receptors(SSTR)
SSTR₁ SSTR_{2a} SSTR₃ SSTR₄ SSTR₅

Immunohistochemical detection of SSTR2a

Ferone D et al. J of Mol Endocrinol 42: 361-370, 2009

	Score 0	Score 1	Score 2	Score 3
				
				
	SUBCELLULAR PATTERN			
(Negative)		Pure cytoplasmic	Membranous usually incomplete	Membranous circumferential
	EXTENSION OF POSITIVE TUMOR CELL POPULATION			
(Absent)		1-100%	<50%	>50%
	CONCORDANCE WITH OCTREOSCAN DATA			
	50%	54%	87%	94%

Schematic illustration of somatostatin receptor type 2A immunohistochemical scoring system and its concordance rate with ¹¹¹In-pentetreotide *in vivo* imaging.

Volante M et al. Modern Pathology 20:1172-82,2007

References

1.HER2 in Breast and Gastric cancers.

Wolff AC, Hammond ME, Schwartz JN, Hagerty KL, Allred DC, Cote RJ, Dowsett M, Fitzgibbons PL, Hanna WM, Langer A, McShane LM, Paik S, Pegram MD, Perez EA, Press MF, Rhodes A, Sturgeon C, Taube SE, Tubbs R, Vance GH, van de Vijver M, Wheeler TM, Hayes DF; American Society of Clinical Oncology/College of American Pathologists American Society of Clinical Oncology/College of American Pathologists guideline recommendations for human epidermal growth factor receptor 2 testing in breast cancer. Arch Pathol Lab Med. 2007;131(1):18-43

Hammond ME, Hayes DF, Dowsett M, Allred DC, Hagerty KL, Badve S, Fitzgibbons PL, Francis G, Goldstein NS, Hayes M, Hicks DG, Lester S, Love R, Mangu PB, McShane L, Miller K, Osborne CK, Paik S, Perlmutter J, Rhodes A, Sasano H, Schwartz JN, Sweep FC, Taube S, Torlakovic EE, Valenstein P, Viale G, Visscher D, Wheeler T, Williams RB, Wittliff JL, Wolff AC. American Society of Clinical Oncology/College of American Pathologists guideline recommendations for immunohistochemical testing of estrogen and progesterone receptors in breast cancer. Arch Pathol Lab Med. 2010 Jun;134(6):907-22.

Mansfield AS, Sukov WR, Eckel-Passow JE, Sakai Y, Walsh FJ, Lonzo M, Wiktor AE, Dogan A, Jenkins RB. Comparison of fluorescence in situ hybridization (FISH) and dual-ISH (DISH) in the determination of HER2 status in breast cancer. Am J Clin Pathol. 2013 Feb;139(2):144-50.

Astrid Hirschmann,¹ Tiffany Ann Lamb, PhD,² Georges Marchal,³ Mary Padilla, MD,⁴ and Joachim Diebold, MD¹ Simultaneous Analysis of HER2 Gene and Protein on a Single Slide Facilitates HER2 Testing of Breast and Gastric Carcinomas Am J Clin Pathol 2012;138:837-844

Hofmann M, Stoss O, Shi D, Büttner R, van de Vijver M, Kim W, Ochiai A, Rüschoff J, Henkel T. Assessment of a HER2 scoring system for gastric cancer: results from a validation study. Histopathology. 2008 Jun; 52(7):797-805.

Rüschoff J, Hanna W, Bilous M, Hofmann M, Osamura RY, Penault-Llorca F, van de Vijver M, Viale G. HER2 testing in gastric cancer: a practical approach. Mod Pathol. 2012 May; 25(5):637-50.

2.Lung cancer and EGFR and ALK

Sasaki H, Endo K, Konishi A, Takada M, Kawahara M, Iuchi K, Matsumura A, Okumura M, Tanaka H, Kawaguchi T, Shimizu T, Takeuchi H, Yano M, Fukai I, Fujii Y. EGFR Mutation status in Japanese lung cancer patients: genotyping analysis using LightCycler. Clin Cancer Res. 2005 Apr 15;11(8):2924-9.

Jian Yu et al. Mutation-Specific Antibodies for the Detection of EGFR Mutations in Non-Small-Cell Lung Cancer Published Online First on April 14, 2009 as 10.1158/1078-0432.CCR-08-2739

Kosaka T, Yatabe Y, Endoh H, Kuwano H, Takahashi T, Mitsudomi T.

Mutations of the epidermal growth factor receptor gene in lung cancer: biological and clinical implications. Cancer Res. 2004 Dec 15;64(24):8919-23.

Gazdar AF. Activating and resistance mutations of EGFR in non-small-cell lung cancer: role in clinical response to EGFR tyrosine kinase inhibitors. Oncogene. 2009 Aug;28 Suppl 1:S24-31

Yoshida T, Zhang G, Haura EB. Targeting epidermal growth factor receptor: central signaling kinase in lung cancer. *Biochem Pharmacol.* 2010 Sep 1;80(5):613-23.

Jiang G, Fan C, Zhang X, Dong Q, Wang L, Liu Y, Dai S, Yang L, Zhang Y, Yu J, Wang E. Ascertaining an Appropriate Diagnostic Algorithm Using EGFR Mutation-Specific Antibodies to Detect EGFR Status in Non-Small-Cell Lung Cancer. *PLoS One.* 2013;8(3):e59183.

Soda M, Choi YL, Enomoto M, Takada S, Yamashita Y, Ishikawa S, Fujiwara S, Watanabe H, Kurashina K, Hatanaka H, Bando M, Ohno S, Ishikawa Y, Aburatani H, Niki T, Sohara Y, Sugiyama Y, Mano H. Identification of the transforming EML4-ALK fusion gene in non-small-cell lung cancer. *Nature.* 2007 Aug 2;448(7153):561-6. Epub 2007 Jul 11.

Shaw AT, Yeap BY, Mino-Kenudson M, Digumarthy SR, Costa DB, Heist RS, Solomon B, Stubbs H, Admane S, McDermott U, Settleman J, Kobayashi S, Mark EJ, Rodig SJ, Chirieac LR, Kwak EL, Lynch TJ, Iafrate AJ. Clinical features and outcome of patients with non-small-cell lung cancer who harbor EML4-ALK. *J Clin Oncol.* 2009 Sep 10;27(26):4247-53.

3. Colo-rectal cancer and KRAS

Behl AS, Goddard KA, Flottemesch TJ, Veenstra D, Meenan RT, Lin JS, Maciosek MV. Cost-effectiveness analysis of screening for KRAS and BRAF mutations in metastatic colorectal cancer. *J Natl Cancer Inst.* 2012 Dec 5;104(23):1785-95.

Nakamoto K, Nagahara H, Maeda K, Noda E, Inoue T, Yashiro M, Nishiguchi Y, Ohira M, Hirakawa K. Expression of E-cadherin and KRAS mutation may serve as biomarkers of cetuximab-based therapy in metastatic colorectal cancer. *Oncol Lett.* 2013 Apr;5(4):1295-1300.

Hebbar M, Wacrenier A, Desauw C, Romano O, Cattani S, Triboulet JP, Pruvot FR. Lack of usefulness of epidermal growth factor receptor expression determination for cetuximab therapy in patients with colorectal cancer. *Anticancer Drugs.* 2006 Aug;17(7):855-7.

Atkins D, Reiffen KA, Tegtmeier CL, Winther H, Bonato MS, Störkel S. Immunohistochemical detection of EGFR in paraffin-embedded tumor tissues: variation in staining intensity due to choice of fixative and storage time of tissue sections. *J Histochem Cytochem.* 2004 Jul;52(7):893-901

4. Gastrointestinal stromal tumor (GIST)

Miettinen M, Makhlof H, Sobin LH, Lasota J. Gastrointestinal stromal tumors of the jejunum and ileum: a clinicopathologic, immunohistochemical, and molecular genetic study of 906 cases before imatinib with long-term follow-up. *Am J Surg Pathol.* 2006 Apr;30(4):477-89.

Nishida T, Takahashi T, Miyazaki Y. Gastrointestinal stromal tumor: a bridge between bench and bedside. *Gastric Cancer.* 2009;12(4):175-88.

Doyle LA, Nelson D, Heinrich MC, Corless CL, Hornick J. Loss of succinate dehydrogenase subunit B (SDHB) expression is limited to a distinctive subset of gastric wild-type gastrointestinal stromal tumours: a comprehensive genotype-phenotype correlation study. *Histopathology.* 2012 Nov;61(5):801-9.

Rege TA, Wagner AJ, Corless CL, Heinrich MC, Hornick JL. "Pediatric-type" gastrointestinal stromal tumors in adults: distinctive histology predicts genotype and clinical behavior. *Am J Surg Pathol.* 2011 Apr;35(4):495-504.

.Fatima N, Cohen C, Siddiqui MT. DOG1 utility in diagnosing gastrointestinal stromal tumors on fine-needle aspiration. *Cancer Cytopathol.* 2011 Jun 25;119(3):202-8.

Kang GH, Srivastava A, Kim YE, Park HJ, Park CK, Sohn TS, Kim S, Kang DY, Kim KM. DOG1 and PKC- θ are useful in the diagnosis of KIT-negative gastrointestinal stromal tumors. *Mod Pathol.* 2011 Jun;24(6):866-75

Novelli M, Rossi S, Rodriguez-Justo M, Taniere P, Seddon B, Toffolatti L, Sartor C, Hogendoorn PC, Sciot R, Van Glabbeke M, Verweij J, Blay JY, Hohenberger P, Flanagan A, Dei Tos AP. DOG1 and CD117 are the antibodies of choice in the diagnosis of gastrointestinal stromal tumours. *Histopathology.* 2010 Aug;57(2):259-70

Wong NA, Shelley-Fraser G. Specificity of DOG1 (K9 clone) and protein kinase C theta (clone 27) as immunohistochemical markers of gastrointestinal stromal tumour. *Histopathology.* 2010 Aug;57(2):250-8.

Lopes LF, West RB, Bacchi LM, van de Rijn M, Bacchi CE. DOG1 for the diagnosis of gastrointestinal stromal tumor (GIST): Comparison between 2 different antibodies.

Appl Immunohistochem Mol Morphol. 2010 Jul;18(4):333-7.

5. Neuroendocrine tumors and SSTR

Ferone D, Gatto F, Arvigo M, Resmini E, Boschetti M, Teti C, Esposito D, Minuto F. The clinical-molecular interface of somatostatin, dopamine and their receptors in pituitary pathophysiology. *J Mol Endocrinol.* 2009 May;42(5):361-70.

Volante M, Brizzi MP, Faggiano A, La Rosa S, Rapa I, Ferrero A, Mansueto G, Righi L, Garancini S, Capella C, De Rosa G, Dogliotti L, Colao A, Papotti M. Somatostatin receptor type 2A immunohistochemistry in neuroendocrine tumors: a proposal of scoring system correlated with somatostatin receptor scintigraphy. *Mod Pathol.* 2007 Nov;20(11):1172-82.

Papotti M, Bongiovanni M, Volante M, Allia E, Landolfi S, Helboe L, Schindler M, Cole SL, Bussolati G. Expression of somatostatin receptor types 1-5 in 81 cases of gastrointestinal and pancreatic endocrine tumors. A correlative immunohistochemical and reverse-transcriptase polymerase chain reaction analysis. *Virchows Arch.* 2002 May;440(5):461-75